

Hyaluronic Acid: A Safe, Biodegradable and Biocompatible Product for Buttock Augmentation and Contouring

Sabet Salahia, Tariq Mehmood Dar

ABSTRACT

Introduction: Attractive buttocks are one of the traits of sexual appeal and it is said that the universally accepted ideal female shape is a Waist-to-Hip Ratio of 0.7. In the late 90s, Hyaluronic Acid (HA) fillers, a facial aesthetic injectable was introduced which is the minimally invasive technique and is widely used. As per the Cosmetic Surgery National Data Bank Statistics for 2019, HA is the 2nd most nonsurgical procedure advanced by botulinum toxin.

Methodology: The study is a single-center, prospective study conducted at Cosmesurge Plastic Surgery Hospital and Clinics with Eikonha (HA gel) injection at a concentration of 200 ml for 12-18 months. The study was performed in two patients with age 29 and 45 years.

Results: The dose of HA injected in the procedure is 200 ml per session with an approximate dose of 100 ml of HA for each buttock. The injection is injected into the deep sub-dermal layer and subcutaneous fat above muscle fascia. No complications are associated with the treatment except for the minute injection points which automatically disappear once they are healed. This treatment showed effective and desired outcomes as perceived by the individuals without any safety concerns.

Conclusion: Despite being a bioabsorbable filler, outcomes of the study encourage the use of HA-based dermal fillers especially for buttock augmentation and contouring.

Keywords: Buttock augmentation and contouring, deep dermis, HA Fillers, nonsurgical procedures, subcutaneous fat.

Submitted : April 24, 2022

Published : May 17, 2022

ISSN: 2593-8339

DOI: 10.24018/ejmed.2022.4.3.1344

S. Salahia

Cosmesurge Clinics & Cosmesurge Hospital, Dubai, UAE.

(e-mail: drsabet@hotmail.com)

T. M. Dar*

AK Pharma Pvt. Ltd. Pakistan.

(e-mail: drtariqdar@gmail.com)

*Corresponding Author

I. INTRODUCTION

One of the largest growing sectors of plastic surgery is “Aesthetic Surgery of the Buttocks” [1]. Attractive buttocks are one of the traits of sexual appeal and it is said that universally accepted ideal female shape is Waist-to-Hip Ratio of 0.7. Men find women with this ratio as the most attractive body shape i.e., full buttocks and narrow waist [1], [2]. So, the field of buttock contouring and augmentation has growing demand and consideration in this new epoch [1]. The following Fig. 1 and Table I represent the ethnic standards and preferences for attractive buttocks.

The following are the widely available buttock augmentation procedures used:

- Gluteal augmentation with implants
- Autologous fat grafting
- Local flaps
- Hyaluronic acid gel injection, and
- Local tissue rearrangement [2]

Gluteal augmentation, despite its growing interest in body contouring, is associated with many surgical complications like anesthesia reactions, toxicity from Xylocaine or

epinephrine, numbness and augmentation/ contouring complications like unevenness or irregularities [4], [5]. Subjects who intended to for buttock augmentation generally prefer non-surgical, scarless, safe and economic procedures [6]. With the advent of technology and contemporary methods, non-invasive treatment options have gained their importance in buttock contouring and augmentation because of their reduced risk of complications [3]. Many dermal fillers are available which include polyalkylimide gel, polyacrylamide gel, polymethylmethacrylate and Hyaluronic Acid (HA) [7]. In late 90s, HA fillers, a facial aesthetic injectable was introduced which is the minimally invasive technique and is widely used [7], [8].

HA is a non-animal-based glycosaminoglycan biopolymer. It is naturally synthesized in the body and can be artificially synthesized and used as dermal fillers for aesthetic preferences [7]. It is approved by regulatory agencies in Europe and U.S. Federal Drug Administration (FDA) and is primarily indicated for the treatment of wrinkles and trough augmentation [9]. Many HA based products are available in the market in different concentrations, degree of cross-linking of polymers, particle size, and elastic modulus. Based on the

physical and chemical nature of the compound, it can be used for different indications at different sites [7].

HA has been used for many years with mild side effects, first-rate efficacy profile and is well accepted worldwide. Composition of stabilized HA includes a greater part of the water of about 98% and HA of 2%. It is biodegradable, biocompatible within the tissue and objectively takes up the volume, unlike implants. Its biodegradable, biocompatible nature makes its use temporary and requires reassessment and retreatment within then time [10].

The present study is a prospective observational, single-centre assessing the safety and efficacy of HA gel (Brand name: Eikonha 20 mg/ml) for buttock augmentation and contouring.

All procedures performed in studies involving human participants were in accordance with the ethical standards of the international rules of sterility and safety. Written informed consent was obtained from the patient.

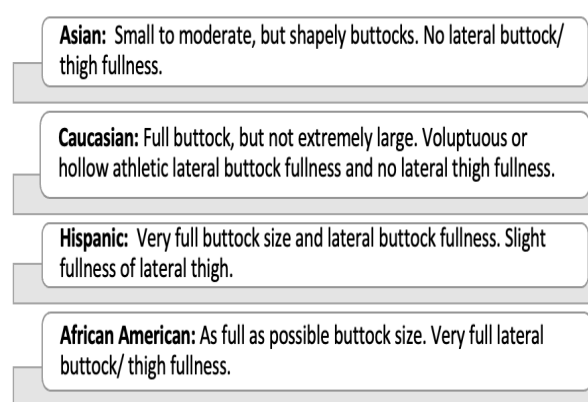


Fig. 1. Ethnic standards for attractive buttocks [1].

TABLE I: ATTRACTIVE BUTTOCK PREFERENCES [4]

	Most Attractive (%)	Next Most Attractive (%)
Posterior View		
Waist-to-hip ratio	0.64 (44.2)	0.60 (25.0)
Vertical ratio for lateral prominence	Inferior gluteal convexity (26.3)	70:30 (23.6)
Lateral View		
Waist-to-hip ratio	0.70 (29.8)	0.725 (22.4)
Vertical ratio for lateral prominence	50:50 (45.1)	40:60 (37.5)

A. Eikonha – HA Gel

Eikonha (HA gel) is a brand of AK Pharma, Inc., USA. Eikonha is the next generation cross-linked hyaluronic acid based dermal filler with 20 mg/ml concentration. Eikonha is designed for architectural reshaping of body, based on Enhanced Interlinked 3D Matrix (EIM) technology which allows easy to inject, natural looking and long-lasting effect [11]. Eikonha is available in 10 ml and 20 ml sterilized prefilled syringes. The particle size of HA in Eikonha is between 0.5-1.25 mm and its durability is 12-18 months.

II. METHODOLOGY

Study design: The study was performed in two patients with age 29 and 45 years. It is a single-centre, prospective

study conducted at Cosmesurge Plastic Surgery Hospital and Clinics (Dubai) with Eikonha (HA gel) injection at a volume of 100 ml at each side (Buttock) for 12-18 months.

A. Patient Eligibility

Evaluating, assessing the right patients, and excluding the patients who are not the right candidate for the treatment is critically important to attain a perfect aesthetic effect.

1) Inclusion criteria

- Subjects ≥ 18 years of age
- Individuals looking for buttock augmentation
- The selection of candidates is based on the percentage of body fat. Those subjects with fat of $<20\%$ or at a range of $>20\%$ - $<30\%$ are suitable for fillers. Individuals with fat $>30\%$ are ideally recommended for weight loss.

2) Exclusion criteria

Individuals with the following conditions are contraindicated and excluded for augmentation:

- With permanent fillers
- Autoimmune diseases
- Known allergies to HA and its components
- Susceptibility to keloids
- Current treatment with steroids
- Pregnancy and lactation
- With age < 18 years
- With bleeding disorders
- Use of anti-platelets, anticoagulants, thrombolytics

B. Site Selection

The entire procedure is carried out with confidentiality and comfort in our hospital located at Jumeirah, Dubai, UAE.

C. Informed Consent

A written informed consent form is obtained from the individuals who are prepared and are the candidates for buttock contouring and augmentation. Subjects are informed about the detailed procedure, components used for the treatment, safety concerns to expect during and after the treatment to maintain transparency. Individuals are elucidated about the duration of treatment, risk factors involved and to manage the possible complications if any.

Our study is single centre, prospective analysis performed at Cosmesurge Plastic Surgery Hospital and Clinics, Dubai in two female patients. The age of the patients are 29 years and 45 years. A detailed description of the procedure is given below:

D. Pre-procedure

Using HA for buttock contouring and augmentation is almost comparable to the dermal fillers used for face augmentation. It ensures optimum efficacy with no or minimal side effects. Preferred candidates used for buttock augmentation in our study are those who are looking to enhance their buttocks because they have lost their natural curvature due to age or weight loss and want to reshape them to round.

A detailed review of individual medical history is done prior to surgery to know if any complications associated. After a thorough review of medical history, the subject is assessed for the area that is likely to be treatable and

discussed the outcome she is likely looking to achieve. We also offered a 14-day cooling off period, if they are supposed to change their intention about the treatment.

Before the intervention, photos were taken, local anesthesia was applied to the buttock area and will be completely numbed to prevent the pain or discomfort the injections cause.

E. Procedure

Fig. 2 below shows the photograph of the patients before the intervention, in order to distinctly notice the difference after the procedure. Specific injection area from the back and sides is determined before the procedure itself and the individual is examined in the up-right position as lying down augments the natural gravity and shape. The individual is marked with the injection points evidently in the upper gluteal and sub-gluteal areas. Later, after markings, subjects are disinfected at the surgical area and local anesthesia is given to the buttock area.

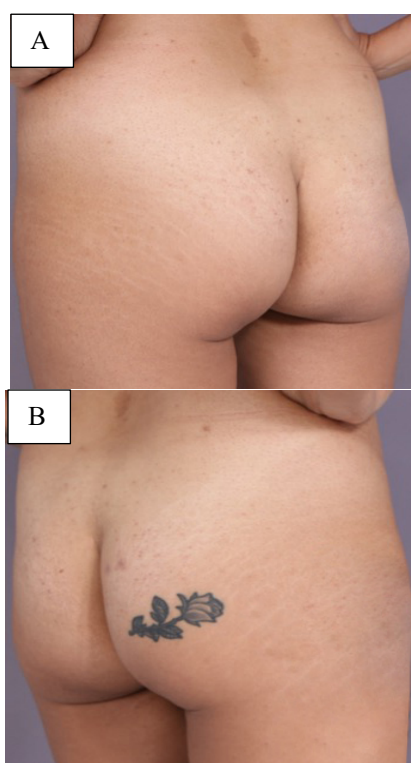


Fig. 2. Buttocks of patients before the intervention. Fig. 2A: Patient 1, 29 years old; Fig. 2B: Patient 2, 45 years old.

Lidocaine (10ml/100 saline, 2% in 2 ml sodium bicarbonate), a local anaesthesia is applied with 18G to create an opening for the 18G fat transfer cannula. Following this, HA gel (Eikonha) is applied with the help of a fine cannula which is of 2mm diameter and 150mm length using the fanning injection technique. The gel is injected into the upper gluteal region, which lifts up the gluteal area as well as the sub-gluteal crease. For accurate results, individuals were allowed to stand so as to overlook for natural gravity and shape and correct the shape and size of the buttock if any.

The dose of HA (Eikonha) injected in the procedure is 200 ml per session with an approximate dose of 100 ml of HA (Eikonha) for each buttock. The injection is injected into the deep sub-dermal layer and subcutaneous fat above muscle fascia. After the application, massage was carried out on the

treated area from bottom to top if necessary, so that the product spreads evenly.

Post massage, individuals can look for the change or reshape of the buttocks immediately. Subjects can also resume their daily routines instantly. The entire treatment took around 45 minutes to 1 hour and was carried out with well-being and confidentiality at our clinic. No complications are associated with the treatment except for the minute injection points which automatically disappear once they are healed. This treatment showed effective and desired outcomes as perceived by the individuals without any safety concerns.

Fig. 3 shows the photograph of the patients pre- and post-intervention and can notice the difference after the procedure.

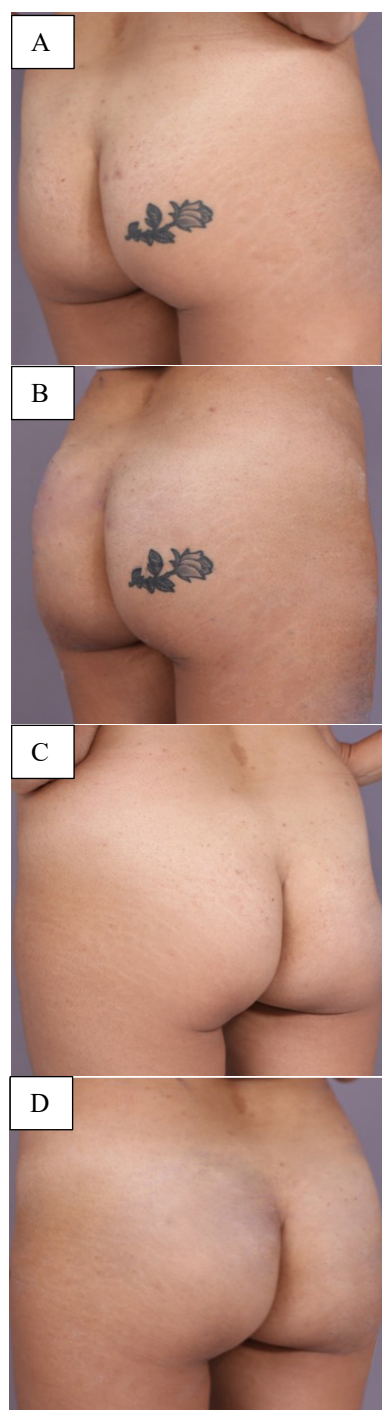


Fig. 3. Buttocks of patients before and after the intervention (reshaping and round buttocks). Fig 3A&3B: before and after for patient 1, 45 years old; Fig. 3C&3D: before and after for patient 1, 29 years old;

F. Post-procedure

Post-procedure, the application area is dressed up with a disinfectant so as to avoid further infections. It is generally recommended to continue for at least three days in order to keep it dry.

Since the procedure involves an injection, there might be slight swelling and redness. The subject may feel firm for a few days which gradually gets softer and take a natural shape. Prescribing Augmentin 1 gm BD for 5 days orally for infection control and Arcoxia 90 mg for 5 days orally recommended to avoid any swelling or redness and it is auto subsiding in 2-3 weeks.

For 1-week post-treatment following precautions were recommended:

- Avoid heavy workouts
- Avoid consuming an excess of alcohol
- Avoid exposure to the sun and extreme temperatures
- Avoid steam baths

G. Follow-up

Patients were followed up at 2 weeks, 3 weeks, 4 weeks and at 6, 12, 18 months for subject satisfaction with buttock size, shape, firmness, and physical appearance. Both the patients are extremely satisfied with no treatment related side effects.

III. DISCUSSION

Aesthetic dermatology has gained its popularity in recent times and among these, injectable dermal fillers is demanding [12], [13]. Acceptance of dermal fillers is due to its invasive nature, less salvage time, easy availability, greater efficacy and minor side effects [10], [12]. Dermal fillers are available in both absorbable and nonabsorbable forms. HA, collagen, calcium hydroxylapatite, and poly-L-lactic acid are absorbable fillers whereas polymethylmethacrylate is the only nonabsorbable filler available [12]. As per the Cosmetic Surgery National Data Bank Statistics for 2019, HA is the 2nd most nonsurgical procedures advanced by botulinum toxin [14].

HA is sometimes referred to as hyaluronan or hyaluronate, and is a naturally occurring component [15]. It is chemically a glycosaminoglycan polysaccharide composed of alternating residues of the monosaccharide d-glucuronic acid and N-acetyl-d-glucosamine [16]. It is an integral component of the extracellular matrix of the dermis and acts as a supporting factor to the tissues [16]. Being the body's natural component (present in almost all biological fluids and tissues), it produces no/less allergic reactions when used as a dermal filler [16], [17]. It is a wound healing agent and acts as a lubricant for joints (a component in the synovial fluid) [16]. It is hygroscopic in nature when not bound to other molecules and is produced by dermal fibroblasts, synovial cells, endothelial cells, smooth muscle cells, adventitial cells, and oocytes [15], [16]. HA even indirectly stimulates neocollagenogenesis after injection by mechanical stretching of the dermis and subsequent activation of dermal fibroblasts [16]. Besides the aesthetic properties, HA also have properties like destroying free radicals and thereby functions in wound healing, ovulation, fertilization, signal transduction, and tumor physiology [18].

Injectable dermal fillers, despite being safe are associated with high cost and may sometimes incur the situation of improper injections by clinicians or sometimes by individuals [12]. Use of the adulterated/ substandard products and self-injections may result in abnormal pigmentation, lymphedema, infection, granulomatous reactions, necrosis, and thromboembolization [12]. Our present study is conducted at Cosmesurge Plastic Surgery Hospital and Clinics and so there is no scope for adulterated/ substandard products and self-injections.

A case report was presented by [19] with evidence of fat embolism syndrome in a forty-six-year-old female who was augmented and contoured with HA injections for buttocks seven times. The case report showed no major systemic illness. The patient is negative for rashes on the body, findings at the injection site and laboratory examinations. The study concluded that patient should be examined for fat embolism syndrome even if there is no findings for petechial rash [19]. In the present study, there was no safety concerns until the follow-up period of 18 months.

Reference [20] conducted a study using HA in eight patients which aimed for volume restoration and shaping of the buttocks. The study showed that there was 56, 36, and 24% of gel persistence in the buttocks even after 6, 12, and 24 months, respectively. There was no gel displacement outside of the buttocks area and more than 50% of the subjects were satisfied with their treatment for 24 months. Results are similar to our present study with HA being well tolerated with no major inflammatory reactions or significant adverse events [20].

Reference [21] in his single-center study with fibroblast-HA filler showed positive long-term outcomes. The case series included 22 patients and were followed for 49.2 months (range, 3-6 years) [21]. Study results were as follows:

- <90% patients were satisfied with the treatment outcomes [21]
- <85% patients informed that injection site was as soft as it was before treatment [21]
- No complications are reported and was well-tolerated [21]

Reference [22] in his conference paper on buttock enhancement presented the safety and efficacy of HA. HA is administered at 50 cc on each side in a superficial and deep subcutaneous plane and the study was conducted in 35 patients. Patients were put with compressive garment or tape in the surgical field for 1-2 days and effectiveness and reabsorption are seen for a period of 6 month-1 year. In 100% of patients, no adverse effects were seen but 10 were retreated for enhancement [22]. This is similar to our study where no adverse events were noticed.

A prospective multicenter study was conducted in sixty-one patients to assess the efficacy and safety of stabilized HA gel for volume restoration and contouring of the buttocks [10]. In this study, a range of 340 ± 62 mL of stabilized HA was injected/subject with incision sites of one per buttock (maximum of two per buttock). Subjects were followed for 24-months and after 6-, 12-, 18-, and 24-months treatment period, buttock appearance was rated as improved or better (i.e., "improved," "much improved," or "very much improved") in 80%, 68%, 42% and 40% respectively. All the patients were well-tolerated and satisfied with HA treatment

after 1 month. No major complications were seen except gel dislocation to the sacral area in one patient [10]. These results were similar to our study with greater tolerance, efficacy and satisfaction rates.

Our present study and the established research papers revealed that HA treatment is safe, effective, well-tolerated with great patient satisfaction even after 24 months after treatment.

IV. CONCLUSION

Our experience conducted in 2 cases suggested that the use of HA when compared to major surgery like the implantation of the prosthesis, offers a better balance between efficacy and safety for good aesthetic results. Finally, HA is well-tolerated with high satisfaction of patients and surgeons because this technique is less invasive and offers improved body image and confidence. It has no/low rate of side effects. Despite being a bioabsorbable filler, the outcomes of the study encourage the use of HA based dermal fillers, especially for buttock augmentation and contouring.

V. FUTURE PROSPECT

The future of HA based dermal filler remains to be positive because of its less invasive risk and its biodegradable property. Further studies need to be carried on a large number of patients and at multi-centres.

CONFLICT OF INTEREST

Authors declare that they do not have any conflict of interest.

REFERENCES

- [1] Lee EI, Roberts TL, Bruner TW. Ethnic considerations in buttock aesthetics. *Semin Plast Surg.* 2009; 23(3): 232-243.
- [2] Oranges CM, Tremp M, di Summa PG, Haug M, Kalbermatten DF, Harder Y, et al. Gluteal Augmentation Techniques: A Comprehensive Literature Review. *Aesthet Surg J.* 2017; 37(5): 560-569.
- [3] Campos L, Humzah D. Buttock augmentation with hyaluronic acid fillers. *The PMFA Journal.* 2021; 8(2).
- [4] Abulezz T. A Review of Recent Advances in Aesthetic Gluteoplasty and Buttock Contouring. *Plast Surg Mod Tech.* 2019; 6(1): 1-10.
- [5] Masarapu V, Wang PS, Gorbachova T. Slow-growing buttock mass after failure of incorporation of autologous fat transfer for gluteal augmentation: ultrasound and MRI features. *Skeletal Radiol.* 2020; 49(10): 1669-1675.
- [6] Serdev NP. Serdev Suture for Buttock's Lift - Ambulatory Scarless Procedure. *The Open Dermatology Journal.* 2012; 6: 33-41.
- [7] Trignano E, Baccari M, Pili N, Serra PL, Rubino C. Complications after breast augmentation with hyaluronic acid: a case report. *Gland Surg.* 2020; 9(6): 2193-2197.
- [8] Hedén P. Update on Body Shaping and Volume Restoration: The Role of Hyaluronic Acid. *Aesthetic Plast Surg.* 2020; 44(4): 1295-1299.
- [9] Ono S, Hyakusoku H. Complications after self-injection of hyaluronic acid and phosphatidylcholine for aesthetic purposes. *Aesthet Surg J.* 2010; 30(3): 442-445.
- [10] De Meyere B, Mir-Mir S, Peñas J, Camenisch CC, Hedén P. Stabilized hyaluronic acid gel for volume restoration and contouring of the buttocks: 24-month efficacy and safety. *Aesthetic Plast Surg.* 2014; 38(2): 404-412.
- [11] Baumann LS, Shamban AT, Lupo MP, Monheit GD, Thomas JA, Murphy DK, et al. Comparison of smooth-gel hyaluronic acid dermal fillers with cross-linked bovine collagen: a multicenter, double-

- masked, randomized, within-subject study. *Dermatol Surg.* 2007; 33 Suppl 2: S128-135.
- [12] Martin DS, Han H, Farley KL. Self Injection of Topical Skin Preparation by Patient Seeking Facial Volume Enhancement: A Case Report. *J Clin Aesthet Dermatol.* 2019; 12(8): 51-54.
- [13] Allepot K, Mojallal A, Gerenton B. Self-injection: Inescapable DIY and real danger? A case study and literature review. *Ann Chir Plast Esthet.* 2021; 66(1): 93-99.
- [14] [Internet] Available form: https://www.surgery.org/sites/default/files/Aesthetic-Society_Stats2019Book_FINAL.pdf.
- [15] INCREASING MUSCULAR VOLUME IN A HUMAN USING HYALURONIC ACID. International search report. 2014 July; International Publication Number: WO 2014/110656 A1.
- [16] Requena L, Requena C, Christensen L, Zimmermann US, Kutzner H, Cerroni L. Adverse reactions to injectable soft tissue fillers. *J Am Acad Dermatol.* 2011; 64(1): 1-34.
- [17] Kogan G, Soltés L, Stern R, Gemeiner P. Hyaluronic acid: a natural biopolymer with a broad range of biomedical and industrial applications. *Biotechnol Lett.* 2007; 29(1): 17-25.
- [18] Salwowska NM, Bebenek KA, Żądło DA, Wcisło-Dziadecka DL. Physicochemical properties and application of hyaluronic acid: a systematic review. *J Cosmet Dermatol.* 2016; 15(4): 520-526.
- [19] Uz İ, Yalçınlı S, Efe M. Fat embolism syndrome after gluteal augmentation with hyaluronic acid: A case report. *Ulus Travma Acil Cerrahi Derg.* 2020; 26: 960-962.
- [20] Camenisch CC, Tengvar M, Hedén P. Macrolane for volume restoration and contouring of the buttocks: magnetic resonance imaging study on localization and degradation. *Plast Reconstr Surg.* 2013; 132(4): 522e-529e.
- [21] Moon KC, Kim KB, Han SK, Jeong SH, Dhong ES. Assessment of Long-term Outcomes of Soft-Tissue Augmentation by Injecting Fibroblasts Suspended in Hyaluronic Acid Filler. *JAMA Facial Plast Surg.* 2019; 21(4): 312-318.
- [22] Fernando Robles M, Robles C, Aires B. Hyaluronic Acid for Buttock Enhancement. Conference: The Aesthetic Meeting 2014 The American Society for Aesthetic Plastic Surgery. 2014.



S. Salahia, Specialist Plastic Surgeon is an expert in all types of breast surgeries, body contouring, surgical and non-surgical solutions for face, and massive weight loss patient management. With more than 30 years of experience in the industry, he has worked as Medical Director at Cosmesurge centers and was also a lecturer at Dubai Medical College from 2000 to 2002. He has been the head of the plastic surgery unit in Rashed hospital from 1999 to 2002. Dr. Sabet is committed to applying careful and precise medical/surgical methods and is highly recognized by both public and professionals in UAE, Syria, Middle East, and worldwide.

Dr. Sabet is an active member of associations like the International Faculty for the American Aesthetic Association and ISAPS. He was the Chairman, Lecturer, and Member of the Scientific Committee in many of the Emirates Plastic Surgery Congress (EPSC) Dubai, UAE, and was the Chairman and Faculty Lecturer in the International Cosmetic Gynaecology Conference (ICGC) – Dubai, UAE (November 2018-2019). He has attended various conferences across the World like WEM International Conference by Sinclair – Barcelona, Spain, DEEP Conference in Cyprus, AMWC Anti-aging Cosmetic Surgery Conference – Monaco, France, etc.

Dr. Sabet has completed his Diploma in Micro-Surgery and Diploma in Plastic Surgery from Rennes University, France.



T. Mehmood Dar is a medical doctor. He earned his MBBS degree from Dow Medical College, Karachi University, Pakistan. He is a Physician and did his postgraduation in Diabetology. Dr. Tariq is a Clinical Research Certified Professional. Currently, he holds a position of Director Marketing & Sales in a multinational pharmaceutical company based at UAE.